

What A Pain!
OMT For Pediatric Rheumatology Cases

A Hope Tobey DO FACOP FAAP C-NMM/OMM
 Associate Professor of ONMM and Pediatrics
 Edward Via College of Osteopathic Medicine -VA
 htobey@vcom.vt.edu
 OMEC October 26 2019

American Academy of Osteopathy

OBJECTIVES:

- Recognize the presentation of three pediatric rheumatologic disorders that are frequently seen in a primary care clinic
- Discuss treatment of these patients from an Osteopathic perspective and incorporate OMT into the treatment plan
- Demonstrate and perform OMT techniques that would be beneficial for children with these disease processes

American Academy of Osteopathy
 Osteopathy for All
 OMEC 19 • engage. empower. excel

General Considerations In Treating Rheumatologic Conditions With OMT

- Remember rheumatologic disorders are systemic disorders
- Thinking about the anatomy of a joint – Articular cartilage is avascular therefore the synovial fluid is responsible for bring nutrients and medications as well as removing waste products and immune complexes.
- Increased sympathetic activity decreases blood flow to the joint
- Freedom of lymphatic drainage is essential to remove potentially damaging waste products. Tendon sheaths are particularly rich in lymphatic vessels

In joints with RA the synovial membrane uses up to 20% more O2

American Academy of Osteopathy

General Considerations Continued

- Edema decreases ROM of the joint leading to fibrosis and therefore even less fluid flow, less waste removal and more joint damage.
- Any disease process that leads to a change in the joint structure will lead to somatic dysfunction at the joint and continuous afferent input into the spinal cord leading to facilitation and somato-somatic or somato-visceral dysfunctions.
- Somatic dysfunction throughout the body can increase mechanical stress on joints

Goals For Treatment

- Goals for treating any patient with a rheumatologic condition
 - Ensure patient and/or family have an understanding of their disease process and treatment plan including any medications
 - Provide emotional support
 - Alleviate pain - this will also help break some of the sympathetic up regulation
 - Decrease inflammation
 - Increase joint perfusion
 - Increase waste removal
 - Decrease mechanical stressors on the joint
 - Maintain (possibly improve) joint function and decrease/prevent further damage

Case 1: A 6yo with Leg Pain



American Academy of Osteopathy

- **CC:** 6 ½ yo female with Bilateral Leg pain
- **HPI:** She c/o mild to moderate, dull, achy and sometimes sharp, **B/L distal tibia and ankle pain**. Initially it was just Right side and Right is still worse then the Left. It occurs every evening since age 2yo but has become worse over the last year. It affects her ability to fall asleep but does not wake her from sleep. Massage and Tylenol help. Increased activity through the day makes it worse and will sometimes bring in on during the day too. There is not a specific activity or movement that triggers it. No known Trauma. She had x-rays of bilateral "lower legs" a year ago that mom reports were normal.
- **ROS:**
 - **Gen:** No fever, chills, fatigue or night sweats.
 - **GI:** No N/V/D/C, No dysuria or changes in urination
 - **MSK:** + ankle pain as above; no other joint pains; No joint stiffness, edema or erythema
 - **Neuro:** No numbness or paresthesia; No loss of bowel or bladder continence
 - **Derm:** No rashes or discoloration

American Academy of Osteopathy

- **PMHX:** ADHD, Seasonal Allergies, Anemia
- **PSHX:** Tonsillectomy age 2
- **ALL:** Ketoconazole causes rash itching and intense burning
- **MEDS:** Adderall, Claritin, Flonase, Multivitamin, Iron
- **FAM HX:** Mother ADHD, Hypothyroid, PCOS, obesity, Spinal fusion s/p MVA; Brother is healthy; Paternal side unknown
- **SOC HX:** Lives with Mother, Brother and Smoky their Cat; They recently moved to the area to be closer to family; No smoke exposure; in 1st grade

American Academy of Osteopathy

Differential For Leg Pain In A Child

<p>Hematologic Hemophilia Sickle Cell</p> <p>Inflammatory Enthesopathy JIA Lupis HSP Psoriatic Arthritis</p> <p>Orthopedic SCFE Legg-Calve- Perthes Developmental Dysplasia of the Hip</p> <p>Non-Inflammatory Growing Pains Fibromyalgia Reflex Sympathetic Dystrophy Conversion Reaction</p>	<p>Infection /Infection related Osteomyelitis Reactive Arthritis Rheumatic Fever Lyme Disease Toxic Synovitis</p> <p>Trauma Fracture Overuse Soft tissue Injury Osgood Schlatter Hypermobility</p> <p>Malignancy Leukemia Neuroblastoma Bone Tumor</p> <p>Somatic Dysfunction</p>
--	---

American Academy of Osteopathy

Physical Exam

- **VS:** Wt 56.8 lbs Ht 49.7 in HR 106 RR 20 BP 92/56 O2Sat 99%
- **GEN:** Well developed well nourished in no distress, Cooperative with exam
- **HEENT:** Normocephalic Atraumatic, No cervical lymphadenopathy
- **CHEST:** Symmetric expansion, CTA b/l A&P, No axillary lymphadenopathy
- **CV:** RRR No M/G/R, 2+ Dorsalis pedis and posterior tibialis pulses
- **ABD:** Soft Nondistended
- **NEURO:** CN 2-12 intact, Patellar and Achilles DTR 2+/4; Normal sensation to light touch in B/L lower extremities
- **SKIN:** No rashes or Nail Pitting



PE Continued:

• **MSK:**

Standing - Right iliac crest elevated, Mild Right Tibial Torsion otherwise all anterior lateral and posterior landmarks in line, Normal medial longitudinal arches

Gait - Fluid with maintained landmark relationships, **She bears her weight further forward on the ball of her right foot/toes, Poor motion through the pelvis and low back with compensating increased motion in the knees**

Seated - Negative seated Kemps, Negative seated log roll, Full foot ankle and Knee AROM and PROM, Negative calcaneus squeeze, Negative tib-Fib squeeze

Supine/Prone/Lateral Recumbent - No tenderness throughout LE, **Right Medial Malleoli** approx 1/4 in superior compared to the left, Full Negative log roll, Negative straight leg raise, Full symmetric b/l Hip PROM



PE Continued:

SOMATIC DYSFUNCTIONS:

Cranial - OA E S SLRR, L condyler compression, Moderate SBS compression, Right torsion

Cervical - AA RR C2-3+5 E RSR C4+6 E RSL

Thoracic - T5-10 N SLRR

Ribs - Right Rib 9 posterior

Lumbar - L1-3 N SLRR L4-5 E RSR

Sacrum - S1+3 RR S2 RL


Pelvis - Positive St Flex RIGHT, Positive ASIS Compression RIGHT, Right ASIS Superior, Right pubic ramus superior, Right PSIS superior, Right Ischial tuberosity Superior

Lower Extremity - Right Posterior fibular head, Right anterior talus, Right subtalar joint restriction



Our Patients Labs – From Their PCP:

CBC - WBC 11 Hgb 11.8 Hct 34.9 Plt 365 Diff- Nml
 CRP - 268 ESR - 4
 BMP - NA 138 K 3.9 Cl 104 Bicarb 22 BUN 4 Creat 0.3 Gluc 72
 RA - 2 (0-14) ANA - 1:40 (1:40-1:60)
 Lyme - Negative
 ASO - Negative



Differential For Leg Pain In A Child







Hematologic Hemophilia Sickle Cell Inflammatory Enthesopathy JIA Lupis HSP Psoriatic Arthritis Orthopedic SCFE Legg-Calve- Perthes Developmental Dysplasia of the Hip Non-Inflammatory Growing Pains Fibromyalgia Complex Regional Pain Syndrome <small>- Allk Reflex Sympathetic Dysrhythmia</small> Conversion Reaction	Infection /Infection related Toxic Synovitis Osteomyelitis Reactive Arthritis Rheumatic Fever Lyme Disease Trauma Fracture Overuse Soft tissue Injury Osgood Schlatter Hypermobility Malignancy Leukemia Neuroblastoma Bone Tumor Somatic Dysfunction
---	---





Pelvic Dx Review

Our Patient's Pelvis – Positive St Flex RIGHT, Positive ASIS Compression RIGHT, Right ASIS Superior, Right Pubic ramus superior, Right PSIS superior, Right Ischial tuberosity Superior

Common Pelvic Diagnoses

Anterior	Posterior	Upslipped(Sup Shear)	Downslip (Inf Shear)	Inflair	Outflair
					





So What Does This Mean For Our Patients MSK Physiology and Function?

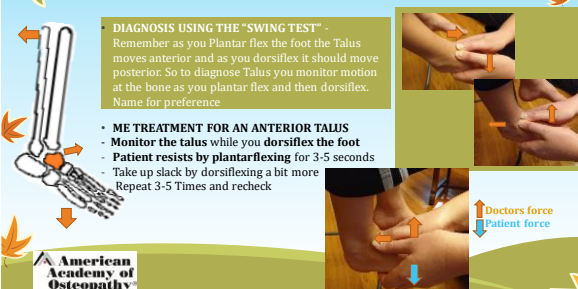
- The Right upslipped innominate pulls the right sacral base superior creating sacral base un-leveling. The lower lumbar sidebend right to compensate.
- This also locks the right SI joint and creates the decreased motion through the lumbar and pelvis when she walks
- The upslipped innominate created a functional short leg (as opposed to an anatomic short leg). In response to this her leg tries to make up the difference by increasing her plantar flexion and putting more weight on the ball of her foot when she walks or runs which over time will cause anterior LE pain.
- The increased plantar flexion also pulls the talus anterior. When the talus is anterior the distal end of the fibula also moves anterior and creates a posterior fibular head.

American Academy of Osteopathy

OMT Treatments That Would Be Beneficial For This Patient

American Academy of Osteopathy

Anterior Talus Muscle Energy Treatment



DIAGNOSIS USING THE "SWING TEST" - Remember as you plantar flex the foot the Talus moves anterior and as you dorsiflex it should move posterior. So to diagnose Talus you monitor motion at the bone as you plantar flex and then dorsiflex. Name for preference

- **ME TREATMENT FOR AN ANTERIOR TALUS**
- Monitor the talus while you dorsiflex the foot
- Patient resists by plantarflexing for 3-5 seconds
- Take up slack by dorsiflexing a bit more Repeat 3-5 Times and recheck


↑ Doctors force
↓ Patient force

American Academy of Osteopathy

DIAGNOSIS:
Grasp the fibular head and try to gently glide it Anterior-Lateral and then posterior-Medial. Name for easier motion.

Posterior Fibular Head Muscle Energy Treatment

- Patient supine or sitting with feet hanging (Not touching the floor)
- Doc stands/sits on the ipsilateral side with one hand in the popliteal fossa so the **MCP joint of the index finger is behind the head of the fibula**. This hand to applies a **gentle Anterior-Lateral pressure on the fibular head**.
- The physicians other hand wraps around the patients foot. Use this hand to **dorsiflex slightly evert the foot while externally rotating the tibia and fibula** to the fibulas anterior restrictive barrier.
- **Patient** gently resists by **internally rotating and plantar flexing** their foot. This isometric contraction is held for 3-5 seconds
- Take up the slack and repeat 3-5 times. Then recheck.




American Academy of Osteopathy

Upslipped Innominate ME Treatment

(AKA: Superior Pelvic Shear)

- Pt supine & doctor holding affected side just **proximal** to the malleoli
- Slightly **abduct** the thigh until it's 'loose'
- **Internally rotate** until tension is reached (close pack the hip joint, locking the fem head into the acetabulum).
- Lean back to maintain moderate traction while supporting unaffected side with your body/your thigh
- Patient pulls their hip gently towards ipsilateral shoulder for 5-7 seconds repeat 3-5 times.
- Return to neutral position and recheck

DIAGNOSIS - (+) StFT on affected side with ASIS, PSIS, Ischial Tuberosity and Pubic Rami superior



RESPIRATORY ASSIST VERSION

- Have Pt take 3-5 deep breaths
- Take up slack by pulling slightly more inferior with each exhalation


American Academy of Osteopathy

Case 2 - 16 yo with Left Heel Pain




American Academy of Osteopathy

• **CC:** 16 yo transgender female who identifies as male with LEFT heel pain
 • **HPI:** He c/o constant mild to moderate, constant, dull, achy, Left heel pain that can become sharp and more intense (5/10) with radiation up the leg to the calf after activity. No edema or erythema. No numbness or tingling.
 He is in Dance (Jazz, Hip hop, tap and Ballet) about 6 -10 hrs a week. His heels feel Ok during dance but hurts the most after class.
 • **ROS:**
 - **Gen:** No fever, chills, fatigue or night sweats.
 - **GI:** No N/V/D/C, No dysuria or changes in urination
 - **MSK:** + ankle pain as above; no other joint pains; No joint stiffness, edema or erythema. Also admits to having "weak" ankles that "roll" frequently.
 - **Neuro:** No numbness or paresthesia; No loss of bowel or bladder continence
 - **Derm:** No rashes or discoloration



• **PMHX:** Transgender female that identifies as male, ADHD, Anxiety
 • **PSHX:** Tonsillectomy 2010 (7yo)
 • **ALL:** Shrimp (face swelling), Sulfa, tree nuts, fish, and kiwi (Rash)
 • **MEDS:** Adderall, Zoloft, Melatonin, Mucinex (PRN) and Epi-Pen
 • **GYN HX:** Menses at age 12yo Regular, G0P0, No prior STIs
 • **FAM HX:** Father WPW, Sister Autism, MGM Breast Ca and HTN
 • **SOC HX:** Lives with Mother and sister, Father not involved, No pets No tobacco use or exposure, No drug use
 • **TRAUMA HX:** Left 5th metatarsal fx 2012 (9yo), Concussion 5/2019 (16yo)



Differential For Heel Pain In A Child

<p>Inflammatory Apophysitis of the calcaneus (Sever's Disease) Enthesitis Juvenile spondyloarthropathies - Juvenile ankylosing spondylitis - Reactive Arthritis (Post infection) - IBD Related Arthritis - Enthesis related Arthritis Psoriatic Arthritis</p>	<p>Infection /Infection related Osteomyelitis Reactive Arthritis</p>
<p>Non-Inflammatory Complex Regional Pain Syndrome - AKA: Reflex Sympathetic Dystrophy</p>	<p>Trauma Fracture Overuse Soft Tissue Injury</p>
<p>Somatic Dysfunction</p>	<p>Malignancy/Tumor - Very Rare Chondrosarcoma (Any age - more common in adults) Osteosarcoma (Teens - dx typically before age 30yo) Ewings Sarcoma (10-20yo) Intraosseous Lipoma (5-85yo) Osteoid Osteoma (10-19yo) Unicameral Bone Cyst (5-15yo)</p>



Physical Exam

- **VS:** Wt 221 lbs Ht 69 in BMI 32.5 HR 97 RR 14 BP 118/82 O2Sat 98%
- **GEN:** Well developed overweight, in no distress, Cooperative with exam
- **CV:** Brisk Capillary Refill, 2+ Dorsalis pedis and posterior tibialis pulses
- **ABD:** Soft Nondistended
- **NEURO:** CN 2-12 intact, Patellar and Achilles DTR 2+/4; Normal sensation to light touch in B/L lower extremities
- **SKIN:** No rashes or Nail Pitting



PE Continued

- **MSK Exam:**
- Gait** - fluid gait no signs of discomfort, No gross asymmetries noted
- Bilateral Foot and Ankle Exam**
- Inspection** - No erythema, effusion or ecchymosis
- Palpation** - No obvious palpable deformities. Tenderness at the distal Achilles over its insertion on the posterior superior calcaneus. No tenderness over the medial or lateral malleoli, base of the 5th metatarsal, navicular, cuboid, metatarsal heads, anterior talofibular ligament, calcaneofibular ligament, posterior talofibular ligament, deltoid ligament or insertion of the plantar fascia on the medial calcaneus. **Negative Squeeze Test.**
- ROM** - Bilateral foot and ankle with full Active and Passive ROM (dorsiflexion, Plantar flexion, inversion, eversion)
- Muscle Strength** - 5/5 bilaterally in the hips (Flexion, Extension, Internal Rotation, External Rotation, Abduction and Adduction) Knees (Flexion, Extension) Ankles (Dorsiflexion, Plantar flexion, Inversion and Eversion) and Great Toes (Flexion and Extension)



PE Continued:

SOMATIC DYSFUNCTIONS:

Cervical - C2-3+6 E RSL C4+5 E RSR

Thoracic - T4-8 N SLRR T 9 F RSR

Ribs - Left Rib 1 Inhaled

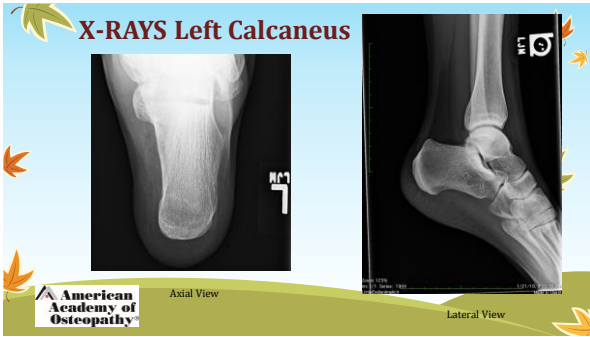
Lumbar - L5 E RSR

Sacrum - L/L Sacral Torsion

Pelvis - Left posterior innominate

Lower Extremity - Bilateral Posterior Fibular head, Bilateral anterior Talus (Left more restricted than right), Significantly restricted Left subtalar joint motion; Left metatarsals 1-4 plantar flexed, bilateral dropped Navicular; Left cuboid dropped.





Differential For Heel Pain In A Child

<p>Inflammatory</p> <ul style="list-style-type: none"> Enthesitis Apophysitis of the calcaneus (Sever's Disease) Juvenile spondyloarthropathies <ul style="list-style-type: none"> - Juvenile ankylosing spondylitis - Reactive Arthritis (Post infection) - IBD Related Arthritis - Enthesis related Arthritis Psoriatic Arthritis <p>Non-Inflammatory</p> <ul style="list-style-type: none"> Complex Regional Pain Syndrome -AKA: Reflex Sympathetic Dystrophy <p>Somatic Dysfunction</p>	<p>Infection /Infection related</p> <ul style="list-style-type: none"> Osteomyelitis Reactive Arthritis <p>Trauma</p> <ul style="list-style-type: none"> Fracture Overuse Soft Tissue Injury <p>Malignancy/Tumor - Very Rare</p> <ul style="list-style-type: none"> Chondrosarcoma (Any age - more common in adults) Osteosarcoma (Teens - dx typically before age 30yo) Ewings Sarcoma (10-20yo) Intraosseous Lipoma (5-85yo) Osteoid Osteoma (10-19yo) Unicameral Bone Cyst(5-15yo)
---	---

Benign



American Academy of Osteopathy logo in the bottom left corner.

Sever's Disease

- Inflammation of the growth plate of the calcaneus caused by overuse of the bone and tendons in a growing child.
- It can involve one or both heels
- Risk Factors** - Starting a new sport or new season
 - Growth spurt (adolescence)
 - Increased weight bearing
 - Excessive traction
 - Over Pronation
- Symptoms** - Pain at the posterior and/or plantar aspect of the heel (over the calcaneal apophysis)
 - Pain is worse with repetitive stress (Sports)
 - Pain can be bad enough to interfere with activities and/or cause a mild limp

Sever's Disease - Cont

- **Exam** - Typically no outward signs of trauma, No erythema or edema
 - NO tenderness or MILD tenderness over the posterior or planter calcaneus
- **POSITIVE CALCANEUS SQUEEZE TEST** - Physician contacts the Medial and Lateral calcaneus with the palms of their hands and compresses the bone. **Pain = positive**
- **Diagnosis** - clinical based on history and exam. X-Rays negative but with growth plate present
- **Treatment** - Pain resolves when activity lessens or bone growth finishes
 - OMT and Stretching hamstring and calf 2-3 x a day
 - Avoid running on hard surfaces
 - Wear well fitting shoes with good support
 - Wear a heel cup and Avoid high-heels

Differential For Heel Pain In A Child

Inflammatory
 Enthesitis
 Apophysitis of the Calcaneus (Sever's Disease)

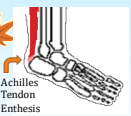
Trauma
 Overuse

Somatic Dysfunction




Enthesitis

- An inflammatory disorder of the enthesis (the attachment of a tendon or ligament to the bone)
- Entesopathy - a disorder of the enthesis but doesn't have to be inflammatory. These terms are often used interchangeably
- Common examples - Osgood-Schlatter, Plantar fasciitis, Achillies tendinopathy





Achilles Tendon Enthesis





Achilles Enthesitis

- Typical cause is chronic traction of the achilles tendon on the calcaneus
- **Risk Factors** - Contracted/shortened calf muscles
 - Sedentary lifestyle
 - Obesity
 - Overuse (sports)
 - Concurrent Spondyloarthropathy
- **Symptoms** - Posterior heel pain while walking/active
- **Exam** - Pain when palpating the achilles tendon at its insertion on the calcaneus -diagnostic
 - Dorsiflexion during palpation will increase pain
- **Diagnosis** - Clinical based on history and exam. No labs needed but recurrent/multifocal enthesitis warrants evaluation for spondyloarthropathy.

Achilles Enthesitis

- **Treatment** - Heel lifts - short term and bilateral
 - OMT
 - PT/ HEP - with a focus on calf muscle stretching
 - Upon awakening take ankle through a full ROM for 1 min to stretch and decrease stress on the achilles tendon
 - Night time splints to provide passive stretch
 - For persistent cases extracorporeal pulse activation therapy (EPAT) could be considered. EPAT used low-frequency pulse waves directed locally to the affected tissues with a goal of stimulating metabolism and enhancing blood circulation, to help regenerate damaged tissue and accelerate healing.

OMT Treatments That Would Be Beneficial For This Patient



Anterior Talus Muscle Energy Treatment

DIAGNOSIS USING THE "SWING TEST" - Remember as you Plantar flex the foot the Talus moves anterior and as you dorsiflex it should move posterior. So to diagnose Talus you monitor motion at the bone as you plantar flex and then dorsiflex. Name for preference

- ME TREATMENT FOR AN ANTERIOR TALUS
- Monitor the talus while you dorsiflex the foot
- Patient resists by plantarflexing for 3-5 seconds
- Take up slack by dorsiflexing a bit more Repeat 3-5 Times and recheck

American Academy of Osteopathy

Posterior Fibular Head Muscle Energy Treatment

DIAGNOSIS: Grasp the fibular head and try to gently glide it Anterior-Lateral and then posterior-Medial. Name for easier motion.

- Patient supine or sitting with feet hanging (Not touching the floor)
- Doc stands/sits on the ipsilateral side with one hand in the popliteal fossa so the MCP joint of the index finger is behind the head of the fibula. This hand to applies a gentle antero-Lateral pressure on the fibular head.
- The physicians other hand wraps around the patients foot. Use this hand to dorsiflex slightly evert the foot while externally rotating the tibia and fibula to the fibulas anterior restrictive barrier.
- Patient gently resists by internally rotating and plantar flexing their foot. This isometric contraction is held for 3-5 seconds
- Take up the slack and repeat 3-5 times. Then recheck.

American Academy of Osteopathy

Ligamentous Articular Release Calcaneus (Bootjack Technique)

- Patient supine with Dr on the affected side facing the foot of the table
- Flex the patients hip and knee. Rest their knee against your side and put your arm that is closest to them over their leg stabilizing their knee into your side. Grasp and stabilize their calcaneus with this thumb and index finger.
- Lean your body back towards the patients head thus bringing the knee into deeper flexion and thus exerting traction on the calcaneus.
- While bringing the heel distally, use your other hand to balance the foot by grasping the forefoot placing your thumb under the distal 1st metatarsal and wrapping your 4th and 5th fingers around the lateral foot.
- Take the metatarsals and tarsals indirectly to balance between your two hands while you bring the calcaneus inferior.

Indications for this technique:

- Heel Pain
- Calcaneus restriction

American Academy of Osteopathy

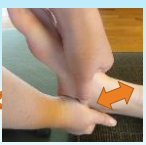

Articulatory Treatment of the Subtalar Joint

Diagnosis

- Patient laying supine with Doc at the foot of the table
- One hand cradles the calcaneus while the other hand draps over the dorsum of the foot with the thumb and index finger grasping the medial and lateral malleoli thereby stabilizing the talus.
- While keeping the foot and ankle at 90 degrees move the calcaneus antero-medially and postero-laterally to check the glide.

To treat (Doc and Patient in the same position) **top hand stabilizes talus bottom hand takes the heel direct into the restriction and add an articulatory impulse** until you feel the tissue soften/loosen

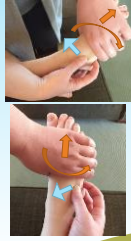
- Recheck the motion


Cuboid Balanced Ligamentous Tension

- Patient supine
- Physician uses one hand to **grasp the cuboid with their thumb and index finger.**
- Your other hand reaches over the dorsal aspect of the foot and your **fingers curl around the whole length of the 4th and 5th metatarsal.**
- **Metatarsals are distracted** gently away from the cuboid until you feel freedom of motion in the joint with the cuboid then **ADDuct and supinate** the metatarsals
- Glide the **cuboid dorsally (superior) and pronate or supinate** to establish a balance point.
- Hold the **balance point** until you feel a softening

Diagnose the Cuboid by gently grasping it and gliding it dorsally with slight pronation or inferior with slight supination



Forefoot
Cuboid



Case 3 – A 12yo Female With Recurrent Left Knee Swelling





• **CC:** 12 yo female with recurrent LEFT knee pain and swelling

• **HPI:** Left knee dull achy pain and swelling off and on for 6 months. Episodes last a couple days to a week but seem to be increasing in the amount of swelling and duration of symptoms with each episode. Currently her pain is 4/10 achy stiffness worse with weight bearing. Her swelling is making it very difficult to walk. Ibuprofen only helps a little with pain but not swelling.

• First episode was noticed during gymnastics but no specific injury occurred and she has been out of gymnastics for the last 4 months with 2-3 additional episodes during that time.

• **ROS:**

- **Gen:** + fatigue; No fever, chills, recent illness or night sweats.
- **GI:** No N/V/D/C, No dysuria or changes in urination
- **MSK:** + Knee pain as above; no other joint pains, No other joint stiffness, edema or erythema.
- **Neuro:** No numbness or paresthesia, No loss of bowel or bladder continence
- **Derm:** No rashes or discoloration



• **PMHX:** Mild Intermittent Asthma

• **PSHX:** None


• **ALL:** Seasonal Environmental

• **MEDS:** Zyrtec and Albuterol PRN

• **FAM HX:** Mother Depression, Brother ADHD, MGM DM and HTN


• **SOC HX:** Lives with Parents, Brother and a Dog in a suburban neighborhood, Mom smokes outside

• **TRAUMA HX:** Fall down a flight of steps at 15mo, Right Ankle Sprain age 10yo



Differential for Knee Swelling

<p>Traumatic</p> <ul style="list-style-type: none"> • Sprain/Strain • Fractures • Ligament injury (MCL, LCL, PCL, ACL) • Meniscus Tear <p>Inflammatory</p> <ul style="list-style-type: none"> • JIA • Osgood-Schlatter • Patellar Tendonitis (Jumpers Knee) • Post Infection Reactive Arthritis 	<p>Infectious</p> <ul style="list-style-type: none"> • Lyme Arthritis • Septic Joint <p>Tumor/Mass</p> <ul style="list-style-type: none"> • Rhabdomyosarcoma • Osteoclastoma • Ewings Sarcoma • Bone Cyst
---	---



Physical Exam

- **VS:** Wt 98 lbs Ht 61 in HR 76 RR 14 BP 110/74 O2Sat 99%
- **GEN:** Well nourished, Well hydrated, In no distress,
- **CV:** Brisk Capillary Refill, 2+ Dorsalis pedis and posterior tibialis pulses
- **ABD:** Soft Nondistended
- **NEURO:** CN 2-12 intact, Patellar reflex on the Left cause discomfort but not on the right. Bilateral Patellar and Achilles DTR 2+ /4; Normal sensation to light touch in B/L lower extremities
- **SKIN:** No rashes or Nail Pitting



PE Continued

- **MSK Exam:**
- Gait** - Antalgic gait - obvious effort to minimize weight bearing on the left leg
- Bilateral Knee Exam**
- Inspection** - LEFT knee effusion, RIGHT No effusion/edema; No erythema or ecchymosis B/L
- Palpation** - LEFT knee with slight warmth. Mild tenderness throughout the LEFT knee No other tenderness of the LEFT lower extremity; Nontender RIGHT knee medial and lateral joint line, patella, medial and lateral posterior edge of the patella, patellar tendon, quad tendon, tibial tuberosity, pes anserine, proximal tibia or fibula
- ROM** - LEFT Knee Active and Passive flexion and extension restricted by effusion; RIGHT Knee with full Active and Passive ROM F/E
- Muscle Strength** - 4/5 LEFT knee in Flexion and Extension -due to discomfort; 5/5 RIGHT knee (F/E) bilateral hips (F/E/Abd/Add) and Ankles (Dorsiflexion, Plantarflexion Inversion and Eversion)
- Special Tests** - LEFT Positive Patellar Ballotement, Negative on the RIGHT; Negative Patellar J sign, Bilateral Anterior and Posterior Drawer, Varus and Valgus Stress, McMurrays (Discomfort but no click on the left)



PE Continued:

SOMATIC DYSFUNCTIONS:

Thoracic - T4-7 N SRRL T8-12 N SLRR

Lumbar - L1-5 N SRRL

Sacrum - L/L

Pelvis - Right Anterior innominate


Lower Extremity - Left Posterior Fibular Head, Left Tibia with Anterior Glide Preference, Left Anterior Talus

Diaphragms - Thoracic inlet preferring compression, flexion and rotation to the left; Abdominal diaphragm preferring exhalation and translation to the right; Pelvic diaphragm with decreased motion and preferring exhalation




Differential for Knee Swelling

<p>Traumatic</p> <ul style="list-style-type: none"> • Sprain/Strain • Fractures • Ligament injury (MCL, LCL, PCL, ACL) • Meniscus Tear <p>Inflammatory</p> <ul style="list-style-type: none"> • JIA • Osgood-Schlatter • Patellar Tendonitis (Jumpers Knee) • Post Infection Reactive Arthritis 	<p>Infectious</p> <ul style="list-style-type: none"> • Lyme Arthritis • Septic Joint <p>Tumor/Mass</p> <ul style="list-style-type: none"> • Rhabdomyosarcoma • Osteoclastoma • Ewings Sarcoma • Bone Cyst
---	---




X-RAY Labs

CBC - WBC 11.3 Hgb 12 Hct 36.4 Plt 325 →
 Diff - Nml
 CRP - 486 ESR - 4
 BMP - NA 143 K 3.5 Cl 102 Bicarb 22
 BUN 4.4 Creat 0.2 Gluc 80
 RA - 3 (0-14) ANA - 1:160 (1:40-1:60)
 Rheumatoid - Negative
 Lyme - ELISA and Western Blot POSITIVE



Differential for Knee Swelling

<p>Traumatic</p> <ul style="list-style-type: none"> • Sprain/Strain • Fractures • Ligament injury (MCL, LCL, PCL, ACL) • Meniscus Tear <p>Inflammatory</p> <ul style="list-style-type: none"> • JIA • Osgood-Schlatter • Patellar Tendonitis (Jumpers Knee) • Post Infection Reactive Arthritis 	<p>Infectious</p> <ul style="list-style-type: none"> • Lyme Arthritis • Septic Joint <p>Tumor/Mass</p> <ul style="list-style-type: none"> • Rhabdomyosarcoma • Osteoclastoma • Ewings Sarcoma • Bone Cyst
---	---



Lyme Arthritis

- Late Lyme (3rd stage) typically presents in Children as Arthritis
- Can occur without any preceding symptoms
- Occurs several months after tick bite
- If patient is treated in stage 1 or 2 of Lyme then the Arthritis almost never develops
- Typically a mono or pauci-articular inflammatory process affecting large joints (especially the knees).
- Swelling/effusion is often remarkable with less pain and less loss of function than expected for the amount of swelling
- Treatment – 28 days of Doxycycline PO or if <8yo Amoxicillin or Cefuroxime
- 10-15% of patients after treatment have a persistent synovitis that lasts months to years
 - ? Etiology - autoimmune vs. slow clearance of nonviable bacteria vs. misdiagnosis
 - Tx with NSAIDS → OMT



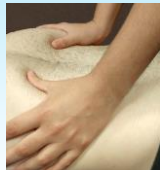OMT Treatments That Would Be Beneficial For This Patient



Treat Those Diaphragms

FIRST Open The Thoracic Duct

Treat The Abdominal Diaphragm



Ischiorectal Fossa (Pelvic Diaphragm) Technique

- Patient supine
- **Superior hand stabilizes ASIS.** Inferior hand pads of fingers on soft tissue at the **medial aspect of ischial tuberosity** -staying along the medial side of the bone
- **Follow the pelvic diaphragm cephalad on exhalation and resist downward motion on inhalation.**
- Done when no further progress or you feel softening, Recheck.
- Treat both sides

Helpful for: Pelvic congestion, Leg Edema, Recurrent sacral dysfunction, pelvic floor dysfunction, pelvic pain

Popliteal Fossa/Diaphragm Release

- Patient Laying supine with knee to be treated slightly flexed (10-15 degrees).
- Physician standing at the feet
- Wrap both hands around either side of the knee Placing fingers parallel in the popliteal fossa
- A gentle anterior pressure is placed to engage the popliteal diaphragm and the a gentle lateral traction is applied to both sides until resistance is felt and then the position is held until a softening is felt.

Depending on amount of effusion and patient discomfort we may not be able to do this one with the first treatment

American Academy of Osteopathy

View from below

Balanced Ligamentous Tension For The Tibia

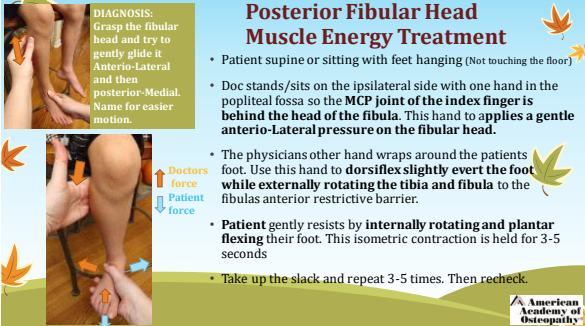
- Patient Supine with Knee bent about 30-45 degrees
- Physician wraps their hands around patients leg with focus on the tibia. Very slight traction is applied to disengage the tibia then very small joint glide motions are checked (Ant/Post/IR/ER/Rt/Lt). Name for preference
- To Treat use the same positioning with gentle inferior traction of the Tibia and gently glide it into is preferred position.
- Hold in this position of balance until you feel a softening
- Recheck


American Academy of Osteopathy

DIAGNOSIS:
Grasp the fibular head and try to gently glide it Anterior-Lateral and then posterior-Medial. Name for easier motion.

Posterior Fibular Head Muscle Energy Treatment

- Patient supine or sitting with feet hanging (Not touching the floor)
- Doc stands/sits on the ipsilateral side with one hand in the popliteal fossa so the **MCP joint of the index finger is behind the head of the fibula**. This hand to applies a **gentle Anterior-Lateral pressure on the fibular head**.
- The physicians other hand wraps around the patients foot. Use this hand to **dorsiflex slightly evert the foot while externally rotating the tibia and fibula** to the fibulas anterior restrictive barrier.
- **Patient** gently resists by **internally rotating and plantar flexing** their foot. This isometric contraction is held for 3-5 seconds
- Take up the slack and repeat 3-5 times. Then recheck.





References:

- AAP – Red Book 31st ed.
- Carriero – An Osteopathic Approach To Children 2nd ed.
- Carriero – Pediatric Manual Medicine An Osteopathic Approach
- DeStefano - Greenman's Principles Of Manual Medicine 5th ed.
- Nicholas - Atlas of Osteopathic Techniques 2nd ed.
- Speece – Ligamentous Articular Strain Osteopathic Manipulative Techniques For The Body
- J Rheumatol. 1991 Dec;18(12):1813-8.
- https://www.kidheart.ac/download/lectures/consfor/emc/es/5_Pediatric%20Rheumatology%20interactive%20course%20series%20-%20181019%20update%2010/181019.pdf
- <https://www.pediatricsonline.com/bacterial-conjunctivitis/update-pediatric-conjunctivitis>
- <https://www.medscape.com/professional/musculoskeletal-and-co-morbidities-by-system?dptid=anr&country=us&from=global&from=global>
- <https://www.ama-assn.org/practicing/education/cme>



Osteopathy for All
OMED 19 • engage. empower. excel
